

PLUMMER'S PATIENT WITH DISTANT METASTASIS CARCINOMA THYROID: A CASE REPORT

M. Bayu Aji Maulana^{1*}, Budi Darmawan², Johan Masjhur³

^{1,2,3}Departemen Kedokteran Nuklir RSHS Bandung PPDS Kedokteran Nuklir

**)Email korespondensi: mbayuajimaulana@gmail.com*

Abstract: Plummer's patient with Distant Metastasis Carcinoma Thyroid: A Case Report. 5% to 10% of patients with papillary thyroid carcinoma (PTC) have locoregional metastases, whereas distant metastases are particularly unusual. Only 4% of thyroid carcinoma (TC) patients develop bone metastases, which makes them poorly understood yet still significantly increases morbidity and mortality. Clinical therapy and rehabilitation might be seriously affected by bone resorption forced on by thyroid cancer. A 58-year-old woman came with complaints of pain in her right groin 5 months before hospital admission. Previously the patient had a history of slipping about 1 year ago and caused walking difficulty. In addition to pain in the groin, the patient feels that his heart is beating frequently, gets tired easily, loses weight, accompanied by hair loss which is felt for about 6 months. Further examination revealed low TSH with Plummer history and also suspected right and left thyroid masses (TIRADS 4). Thyroid scan examination showed cold nodules on both thyroids and bone scan examination found metastatic lesions with pathological fractures in the neck of the right femur accompanied by C5-7 metastatic lesions. Instead of being only the result of tumor invasion into bone, the pathophysiology of bone metastasis seems to represent a cooperative relationship between cancer and the bone microenvironment that results in a "destructive cycle" of bone degradation. Furthermore, follicular and medullary thyroid tumors are more likely to develop bone metastases, suggesting careful bone surveillance in individuals with these histologies. Well-differentiated thyroid carcinoma has a median survival of only 4 years in the presence of bone metastases. Compared to local lymph node and lung metastases, bone metastases are frequently disregarded and understudied. The osseous sites were the preferred sites for distant metastases in thyroid carcinoma linked to Plummer's disease because of their aggressive biological behavior. A missed bone metastasis at an initial diagnosis could have a negative impact on a patient's quality of life and prognosis, even if well-differentiated thyroid cancer is typically indifferent.
Keywords: Plummer Disease, thyroid

Abstrak: Pasien Plummer Disease dengan Karsinoma Tiroid Metastasis.

Sekitar 5% sampai 10% pasien dengan karsinoma tiroid papiler (PTC) memiliki metastasis lokoregional, sedangkan metastasis jauh sangat sedikit ditemui. Metastasis tulang hanya ditemukan pada sekitar 4% dari semua pasien kanker tiroid dan akibatnya kurang banyak dipelajari tetapi tetap berasosiasi dengan morbiditas dan mortalitas yang jauh lebih tinggi. Terapi klinis dan rehabilitasi mungkin sangat dipengaruhi oleh resorpsi tulang yang disebabkan oleh kanker tiroid. Seorang wanita berusia 58 tahun datang dengan keluhan nyeri pada pangkal paha sebelah kanannya sejak 5 bulan sebelum masuk rumah sakit. Sebelumnya pasien memiliki riwayat terpeleset kurang lebih 1 tahun sebelum masuk rumah sakit sehingga kesulitan untuk berjalan. Selain nyeri pada pangkal paha pasien merasakan jantungnya sering berdebar, mudah lelah, berat badan turun, disertai kerontokan pada rambut yang dirasakan kurang lebih 6 bulan sebelum masuk rumah sakit. Pemeriksaan lanjutan menunjukkan kadar TSH rendah dengan riwayat Plummer's disease dan suspek massa tiroid kanan dan kiri (TIRADS 4). Pada pemeriksaan tiroid scan terdapat gambaran cold nodul di kedua thyroid dan bone scan menggambarkan adanya lesi metastasis dengan fraktur patologi pada di collum femur kanan disertai lesi

metastasis C5-7. Patogenesis metastasis tulang nampak menunjukkan asosiasi antara kanker dan lingkungan mikro tulang yang menciptakan "siklus destruktif" penghancuran tulang. Selain itu, tumor tiroid folikuler dan meduler lebih mungkin berkembang menjadi metastase tulang, menunjukkan kebutuhan follow up yang lebih detail pada individu dengan histologi ini. Karsinoma tiroid berdiferensiasi memiliki kelangsungan hidup rata-rata hanya 4 tahun dengan adanya metastasis tulang. Dibandingkan dengan kelenjar getah bening lokal dan metastasis paru, metastasis tulang sering terlewatkan dan tidak banyak diteliti. Kanker tiroid yang terkait dengan penyakit Plummer's menunjukkan perilaku biologis yang agresif dan lebih sering bermetastasis jauh ke area tulang. Meskipun kanker tiroid yang terdiferensiasi dengan baik memiliki progresi yang lambat, metastasis tulang yang terabaikan pada diagnosis awal dapat berdampak buruk pada kualitas hidup dan prognosis pasien.

Kata Kunci: *Plummer Disease*, tiroid

INTRODUCTION

Thyroid cancer is the sixth most prevalent malignancy among women overall and the fifth most common in Indonesia (Bray et al, 2018). Thyroid cancer affects over 440,000 women worldwide each year, 8000 of whom are Indonesian (WHO, 2019). The overall survival rates differ significantly depending on the individual forms of thyroid cancer and the stage of diagnosis, even though the 5-year survival rate is above 95% (Filletti, 2019).

Thyroid cancer is generally classified as a tumor with slow growth and disease course, as well as low morbidity and mortality. Mortality is lowest in individuals under the age of 50 years and increases sharply at the age above (Bray et al, 2018). However, a small proportion are also growing fast and very malignant with a fatal prognosis. The death rate from thyroid carcinoma is only 0.4% of all cancer deaths or around 5 per one million population per year. Geographical conditions affect the prevalence of thyroid cancer types. In coastal areas (Iceland) where iodine consumption is sufficient or sometimes excessive, papillary thyroid cancer is more dominant. In mountains or highlands (Bavaria, Germany) where iodine consumption is deficient, follicular thyroid cancer predominates (Vecchia et al, 2015). Only 4% of thyroid tumors develop in the bones, and distant metastases from thyroid malignancies rarely occur (Filetti,

2019). With a median survival rate of just four years following the diagnosis, bone metastasis is independently associated with a worse prognosis (Osorio et al, 2017).

Distant metastases thyroid cancer with concomitant thyrotoxicosis is rare and poorly recognized, which may result in delayed diagnosis, inappropriate treatment, and even poor prognosis. Thyrotoxicosis is a condition that results from inappropriately high thyroid hormone actions in tissues. Although it commonly manifests palpitations, shortness of breath, increased appetite, sweating, heat intolerance, multiple etiologies and potential therapeutic options may be involved (Gilbert, 2017). In theory, thyrotoxicosis with suppressed TSH should lead to a lower incidence of thyroid cancer than that observed in euthyroid patients (Fiore & Vitti, 2012). In practice, thyroid cancer is typically less efficient in iodine uptake and thyroxine synthesis than normal parenchymal, and most patients with thyroid cancer present with euthyroid or clinical/subclinical hypothyroidism (Kunawudhi et al, 2016). However, an increasing number of studies have demonstrated that more attention should be paid to the management of thyrotoxicosis with concurrent thyroid cancer. Here we present case of Distant Metastasis Thyroid Carcinoma in Plummer patient.

CASE PRESENTATION

Current Medical History:

A 58-year-old woman came with complaints of pain in her right groin for about 5 months before hospital admission, the pain that the patient felt persisted did not radiate, apart from pain the patient felt difficulty walking so that she used a wheelchair, at the groin feels red and swollen. Previously the patient had a history of slipping for about 1-year before hospital admission. After slipping the patient could not walk and only rested in bed for about 1 month.

In addition to pain in the groin, the patient feels that his heart is beating frequently, gets tired easily, loses weight, is accompanied by loss of hair which is felt for about 6 before hospital admission. Various examinations performed by the first hospital to find out the underlying disease and the patient was diagnosed with suspected pathological fracture of the neck of the femur-proximal dextra e.c Metastasis? Bone tumors? Osteomyelitis? Patient has lost more than 15 kg in the last one year. Any medical history and hospital admission were denied. No family history of thyroid problems nor endocrine cancer were reported. The patient did not have any complaint about the large neck lump because there was no direct effect to her daily activities. There was no significant past medical history except her sister who suffered from breast cancer.

Physical examination showed compos mentis patient with normal vital sign. There was no exophthalmus or anemic conjunctiva. We found palpable suture scar with a length of \pm 6 cm and a width of \pm 0.1 cm on the neck without enlargement of the thyroid gland. Thoracic and abdominal regio showed no abnormality. Meanwhile, on the right leg, there was a sutured wound measuring \pm 15 cm in length, \pm 0.5 cm in width. Laboratory examination revealed elevated thyroid hormone levels and low TSH levels. On an ultrasound examination of the thyroid gland, we found suspected right and left thyroid

masses (TIRADS 4). Abdominal ultrasound showed no sign of abnormality. Chest X Ray revealed parenchymal infections with left pulmonary mass as differential diagnosis and accompanied by cardiomegaly. Thyroid scintigraphy examination showed cold nodules on both thyroids. Due to his groin pain complaint, we conducted Lumbosacral X Ray which found spondyloarthrosis at the level of L3-4, L4-5 and L5-S1. We also advancing into lumbosacral MRI which showed sinistroconvex lumbar scoliosis, lumbar degenerative spondyloarthropathy with hypertrophy of the facet joints and endplate degeneration of L3-4, L4-5 and also degenerative disc disease of intervertebral disc L2-3 to L5-S1. Mild stenosis of the spinal canal level L3-4 to L5-S1 due to protrusion of the posterior disc were also found. Next investigation was aimed on her right femur. On the X Ray there was soft-tissue opaque shadow with erosion of the cortex and proximal medulla of the right femur with a suggestive periosteal reaction in the form of a sunburst which indicates suspicious appearance of a soft tissue mass with erosion/destruction of the right cortex and proximal medulla of the right femur. We also performed MRI on her right femur and showed heterogeneous solid lesion with minimal central necrosis in the bone marrow-cortex column of the dextra femur, accompanied by destruction of the proximal cortex of the dextra femur, especially on the postero-medial side, accompanied by involvement of the surrounding soft tissue/muscle without neither joint or neurovascular bundle involvement nor bone abscess. These findings given suggestive of primary bone tumor (chondrosarcoma) or secondary bone tumor (metastasis). Another bone examination was carried out to detect the whole abnormalities. Thoracic CT scan was done and indicated suspicious appearance of primary bone tumor costae 7 posterior sinistra or secondary bone tumor (metastasis) (Figure 1).

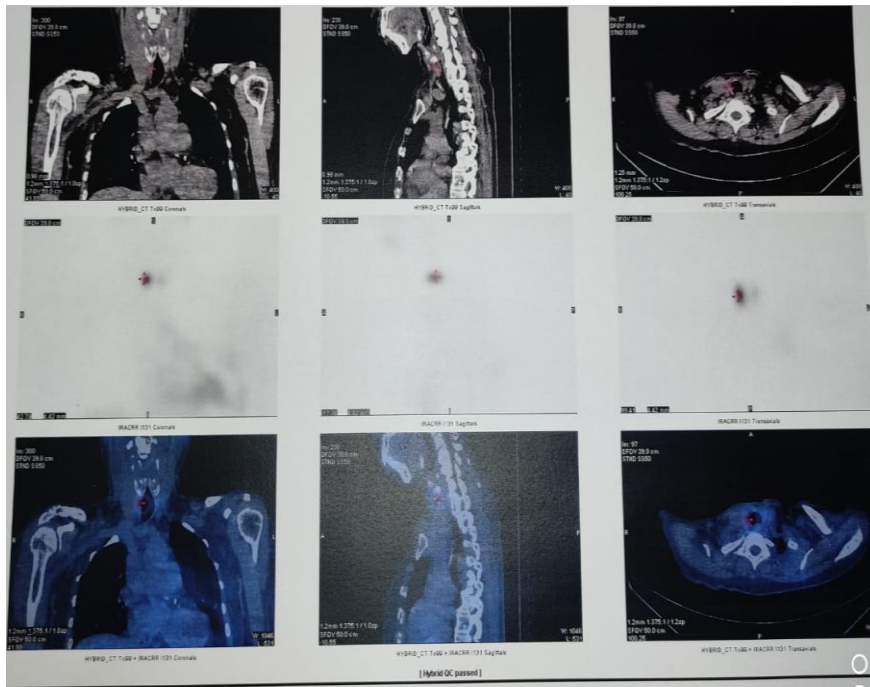


Figure 1. Thoracic CT scan revealed bone tumor in costae 7th

Early ultrasound examination showed bilateral thyroid masses which guided us to do thorough analysis on her thyroid gland. Thyroid hormone profile showed significant increase of peripheral thyroid hormones and suppression of TSHs. Significant changes in some tumor markers were also observed, including NSE tumor and Cyfra 21-2. These two markers were known to be associated with thyroid carcinoma. Our investigation

was confirmed thyroid scintigraphy and bone scan which exhibited bilateral cold nodules and metastatic lesion with pathological fracture in the right femoral neck, respectively. (Figure 2 and 3) Left iliac metastatic lesion on L3,4 vertebrae and suspected c5-7 metastases also exposed in this bone scan. Patient then diagnosed with distant metastasis carcinoma thyroid with the involvement femur, costae, and cervical vertebra.

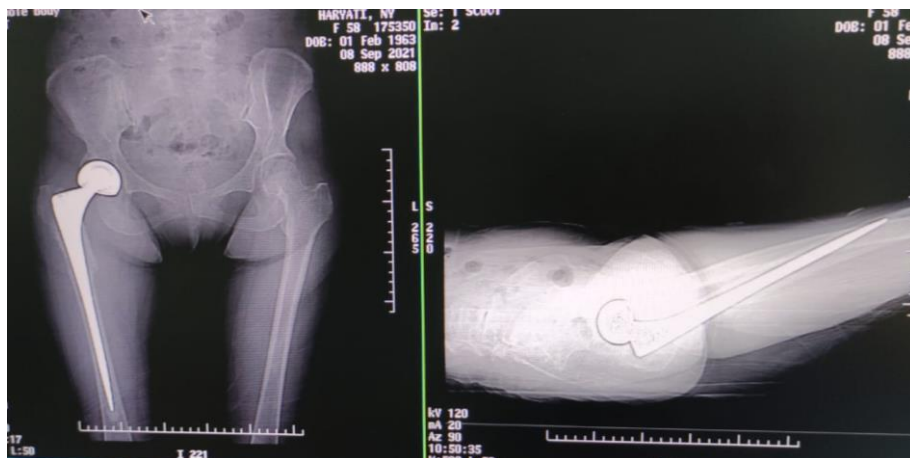

Figure 2. Bone scan showed metastatic lesion with pathological fracture in the right femoral neck

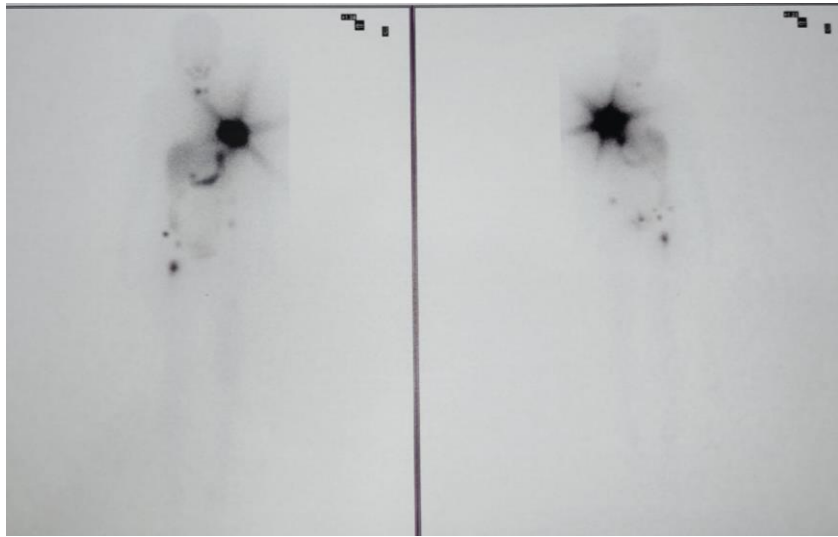


Figure 3. Thyroid scintigraphy exhibited bilateral cold nodules

DISCUSSION

Thyroid cancer and hyperthyroidism are thought to be unique conditions. Delaying a fine needle aspiration biopsy for thyroid nodules that are functional is advised by current guidelines for thyroid nodule evaluation. However, there is a significant number of research on the co-occurrence of thyroid cancer with hyperthyroidism (Cooper et al, 2009). Patients received surgery for the purpose of treating hyperthyroidism in most of these studies. After surgery, cancer was discovered by accident (Gharib, 2010). Due to the presence of cervical lymphadenopathy, questionable ultrasound findings, or negative results from a small needle aspiration biopsy, malignancy was occasionally suspected prior to surgery (Pazaitou-Panayiotou, 2008). Patients with hyperthyroidism who have thyroid carcinoma that was preoperatively or clinically suspected earlier during assessment are even rarer. This present case had more pronounced signs of malignancy with metastasis to the femur, costae, and cervical vertebra (Pazaitou-Panayiotou, 2008).

The presence of thyrotoxic symptoms was confirmed by thyroid scintigraphy, which also demonstrated bilateral cold nodules and elevated peripheral thyroid hormone levels. Among thyroid cancer patients,

hyperthyroidism was seen in 8.3–10.1% of cases (Ardito et al, 1997). Most of the patients are women, with a female-to-male ratio of 2-7:1, and in their middle-to-advanced ages, just like the patients in this research. This reflects the population's propensity for cancer and hyperthyroidism. There does not appear to be a difference in the demography between patients with thyroid malignancies who were identified accidentally and those who had cancer preoperatively suspected or diagnosed (Pazaitou-Panayiotou, 2008).

Thyroid cancer is often identified via ultrasound, confirmed with ultrasound guidance during fine-needle aspiration (FNA), and then classified into three groups based on pathological examinations: differentiated thyroid carcinoma (DTC), anaplastic thyroid carcinoma (ATC), and medullary thyroid carcinoma (MTC). Papillary thyroid carcinoma (PTC), follicular thyroid carcinoma (FTC), Hürthle cell carcinoma (HCC), and poorly differentiated thyroid cancer are other subtypes of DTC. Thyroid cancer has attracted significantly more attention than in the past due to an increase in incidence around the world (Fu et al, 2019).

Skeletal-related events, such as the costae and cervical vertebra pathological fracture, and

destructive-necrotic lesions in femur that were seen in our case, are linked to worse prognosis. Compared to papillary thyroid cancer, follicular thyroid cancer more frequently exhibits bone metastases (Osorio et al, 2017). The spine (34.6%) and pelvic bones (25.5%) are the preference sites, while the thoracic bones and extremities like in our case make up just 18.3% and 10.2% of all bone metastases, respectively. The discovery of bone metastases often occurs by chance because of laboratory or imaging results (Iñiguez, 2020). As a sign of a distant metastasis in our case, we also noticed soft tissue edema around the bone lesion. A metastatic microenvironment for the growth of the metastatic cells may arise because of repeated injury or manipulation, which may lead to chronic inflammation (Allocca, 2019).

External beam radiation and bone remodeling therapy utilizing bisphosphonates are advised in cases of bone metastases. Symptom relief and metastatic progression management are both achievable with high-dose thyroid ablation. Locoregional therapy can improve progression-free survival or cure in cases of oligometastatic bone presentation (Khattak, 2018). In general, radiation combined with surgery improves outcomes, especially for limb-bone lesions. Radiotherapy with 20-30 Gy in 5-10 fractions is indicated if surgery is not an option. Although the effects of palliative radiation often take place two to three days after the treatment, it can alleviate discomfort and other neurological issues (Iñiguez, 2020). Thyroid cancer was detected in up to 2-26.25% of cases of Plummer's illness. This cancer was also discovered in 8.2-29% of autonomously functioning thyroid nodules (AFTN) that were hot or hyperfunctional (Cerci et al, 2007). It is unclear how hyperthyroidism may contribute and coocurrence with thyroid carcinoma. TSH receptor antibodies (TRAB) may play a part in the formation of thyroid nodules and cancer in people with Graves' disease. Both metastatic thyroid cancer and thyroid tumors that

are also associated with hyperthyroidism are considered to have TRAB. In Graves' thyroid cells, TRAB interacts with the TSH receptor to enhance expansion and function (Iñiguez et al, 2020; Cerci et al, 2007). In addition, hyperthyroidism in Plummer's and AFTNs is frequently brought on by mutations in the GS protein or TSH receptor. These mutations cause the cAMP signaling system, which controls thyroid autonomy, to be constantly activated. In thyroid cancer-related functional nodules, the TSH receptor gene alterations have been found. The BRAF and RET/PTC rearrangements have been identified as the most frequently occurring mutations in thyroid cancer (Tfayli, 2010).

The reported course and prognoses for thyroid cancer with or without hyperthyroidism vary as well. The aggressiveness of thyroid cancer did not seem to be affected by Graves' disease. No appreciable differences were seen between patients with Graves' disease and the patients in the euthyroid group in multifocality, lymph node metastasis, distant metastasis, or disease-free survival in the Japanese case-control study by Yano et al (Yano et al, 2007). Similar results were found in numerous other publications that were cited in Pazaitou-Panayoitou's systematic review (Pazaitou et al, 2008). However, there are conflicting and contradictory findings about the aggressiveness of AFTNs and Plummer's illness.

Antithyroid drugs are used to create euthyroidism before surgery is performed as the way of treatment. The full removal of thyroid tissues and all local metastases is advised for all aggressive thyroid malignancies, such as the one in this patient (Cooper et al, 2009). This is frequently true for operations carried out primarily to treat hyperthyroidism or in patients with small, subcentimeter tumors (Hay et al, 2008). On the other hand, current recommendations say that restricted surgery, such as lobectomy, may be sufficient if no other high-risk symptoms are present because the prognosis is typically good. Radioactive iodine was not consistently administered for tiny

tumors in publications that were published (Schroder et al, 1986). Most patients received suppressive dosages of levothyroxine, which is consistent with the recommended course of treatment for thyroid cancer. Studies done in the past reveal that the degree of radioiodine ablation or surgery did not seem to affect the prognosis for hyperthyroid malignancies in the long run.

CONCLUSION

Even though it is uncommon, cancer and hyperthyroidism can coexist. The prognosis is generally excellent, however aggressive cancer can develop. A missed bone metastasis at an initial diagnosis could have a negative impact on a patient's quality of life and prognosis, even if well-differentiated thyroid cancer is typically indifferent. Along with antithyroid drugs used prior to surgery, the treatment regimen is like that used for normal aggressive thyroid cancer.

REFERENCES

- Allocca G, Hughes R, Wang N, et al. (2019). The bone metastasis niche in breast cancer-potential overlap with the haematopoietic stem cell niche in vivo. *J Bone Oncol*. 17:100244. Published 2019 Jun 7.
- Ardito G, Mantovani M, Vincenzoni C, et al. (1997). Hyperthyroidism and carcinoma of the thyroid gland. *Ann Ital Chir*. 68:23-8
- Cerci C, Cerci SS, Eroglu E, et al. (2007). Thyroid cancer in toxic and nontoxic multinodular goiter. *J Postgrad Med*. 53:157-60.
- Cooper DS, Doherty GM, Haugen BR, et al. (2009). The American Thyroid Association (ATA) guidelines taskforce on thyroid nodules and differentiated thyroid cancer revised American Thyroid Association management guidelines for patients with thyroid nodules and differentiated thyroid cancer. *Thyroid*. 19:1167-214.
- F. Bray, J. Ferlay, I. Soerjomataram, R.L. Siegel, L.A. Torre, A. Jemal. (2018). Global cancer statistics 2018: GLOBOCAN estimates of incidence and mortality worldwide for 36 cancers in 185 countries, *CA A Cancer J. Clin*. 68 (1).
- Fiore E, Vitti P. (2012). Serum TSH and risk of papillary thyroid cancer in nodular thyroid disease. *J Clin Endocrinol Metab*. 97(4):1134-1145.
- Fu H, Cheng L, Jin Y, Chen L. (2019). Thyrotoxicosis with concomitant thyroid cancer. *Endocr Relat Cancer*. 26(7):R395-R413.
- Gharib H, Papini E, Paschke R, et al. (2010). American Association of Clinical Endocrinologists, Associazione Medici Endocrinologi and European Thyroid Association medical guidelines for clinical practice for the diagnosis and management of thyroid nodules. *Endocr Pract*. 16(Suppl 1):1-43
- Gilbert J. (2017). Thyrotoxicosis - investigation and management. *Clin Med (Lond)*. 17(3):274-277.
- Hay I, Hutchinson ME, Gonzalez-Losada T, et al. (2008). Papillary thyroid microcarcinoma: a study of 900 cases observed in a 60-year period. *Surgery*. 144:980-8.
- Iñiguez-Ariza NM, Bible KC, Clarke BL. (2020). Bone metastases in thyroid cancer. *J Bone Oncol*. 21:100282.
- Khattak MJ, Ashraf U, Nawaz Z, Noordin S, Umer M. (2018). Surgical management of metastatic lesions of proximal femur and the hip. *Ann Med Surg (Lond)*. Nov 2;36:90-95.
- Kunawudhi A, Promteangtrong C, Chotipanich C. (2016). A case report of hyperfunctioning metastatic thyroid cancer and rare I-131 avid liver metastasis. *Indian J Nucl Med*. 31(3):210-214.
- La Vecchia C, Malvezzi M, Bosetti C, et al. (2015). Thyroid cancer mortality and incidence: a global overview. *Int J Cancer*. 136(9):2187-2195.
- Osorio M, Moubayed SP, Su H, Urken ML. (2017). Systematic review of site distribution of bone metastases in differentiated thyroid cancer. *Head Neck*. 39(4):812-818.
- Pazaitou-Panayiotou K, Perros P, Boudina M, et al. (2008). Mortality from

- thyroid cancer in patients with hyperthyroidism: the Theagenion Cancer Hospital experience. *Eur J Endocrinol.* 159:799–803
- S. Filetti, C. Durante, D. Hartl, S. Leboulleux, L.D. Locati, K. Newbold, M.G. Papotti, A. Berruti. 2019. Thyroid cancer: ESMO Clinical Practice Guidelines for diagnosis, treatment and follow-up, *Ann. Oncol.*
- Schroder DM, Chambors A, France CJ. (1986). Operative strategy for thyroid cancer: is total thyroidectomy worth the price? *Cancer.* 58:2320–8.
- Tfayli HM, Teot LA, Indyk JA, et al. (2010). Papillary thyroid carcinoma in an autonomous hyperfunctioning thyroid nodule: case report and review of the literature. *Thyroid.* 20:1029–32.
- World Health Organization. (2019). The global cancer observatory: *Indoensia, Int. Agency Res. Cancer.* 256 1–2.
- Yano Y, Shibuya H, Kitagawa Q, et al. (2007). Recent outcome of Graves' disease patients with papillary thyroid cancer. *Eur J Endocrinol* 157:325–9.