

## SINUSITIS-INDUCED ORBITAL APEX SYNDROME WITH UNUSUAL PRESENTATION OF FACIAL NERVE PALSY IN HIV-POSITIVE PATIENT

Fernando Nathaniel<sup>1</sup>, Irawaty Hawari<sup>2\*</sup>, Yohanes Firmansyah<sup>3</sup>, Dean Ascha Wijaya<sup>4</sup>

<sup>1-4</sup>Tarumanagara University, Jakarta, Indonesia

Email Korespondensi: irawatih@fk.untar.ac.id

Disubmit: 12 Juli 2023

Diterima: 25 Juli 2023

Diterbitkan: 01 Agustus 2023

Doi: <https://doi.org/10.33024/mnj.v5i8.10962>

### ABSTRACT

*Orbital Apex Syndrome (OAS) is a rare ophthalmological disorder characterized by complex symptoms originating from lesions at the orbital apex. Herein, we report a 60-year-old man with a history of diabetes mellitus and hypertension presented with a swollen left eye and sudden visual loss. He also had nasal symptoms before his admission. Treatment includes broad-spectrum antibiotics and antifungals with additional diabetes management and HIV evaluation. OAS, a severe and uncommon complication of a sinusitis infection, can present with diverse symptoms and cause nerve damage in the orbital apical area. The disease can be easily missed or overlooked when it exhibits atypical symptoms in its initial stages. It is crucial to be vigilant and consider the possibility of complications related to the orbital apex for early detection and appropriate treatment.*

**Keywords:** Facial Nerve Palsy, HIV, Orbital Apex Syndrome, Sinusitis

### INTRODUCTION

Orbital apex syndrome (OAS) is a disorder characterized by loss of vision and paralysis of eye movements caused by nerve injury in the orbital apex region. This can affect structures within the orbital apex, the superior orbital fissure, or the cavernous sinus, leading to various symptoms. When diagnosing OAS, it is important for physicians to determine the location of the lesion and identify its underlying cause.

Accurate diagnosis relies on a thorough clinical assessment, supported by targeted serological and laboratory tests, as well as neuro-imaging techniques like contrast-enhanced Magnetic

Resonance Imaging (MRI) of the brain and orbit, and Computed Tomography (CT) scans. In certain rare cases, a biopsy may be necessary to assist in reaching a definitive diagnosis. Treatment approach varies depending on the specific characteristics of the lesion, with inflammatory conditions typically responding favorably to steroids, while infections generally require appropriate antimicrobial agents.

This study aims to describe the case of orbital apex syndrome in one patient from our institution. A review of this condition is also discussed.

## RESEARCH METHODOLOGY

### Case Report

A 60-year-old man attended the hospital emergency department with a chief complaint of a swollen left eye. The family stated that the patient complained of swelling in the left eye 13 days before admission. Initially, complaints of watery eyes, pain, redness of the skin around the eyes, and numbness in the eye and forehead area. With a gradually decreased appetite. Two days after complaints of the swollen eye appeared, the patient could not see at all, which suddenly occurred when he woke up; the swelling was getting bigger, the eyelids were difficult to open, and headaches occurred. Within three days before admission, symptoms of weakness appeared. One month before admission, the patient had recurrent runny nose. Complaints of sore eyes, hearing loss, ear discharge, stiff neck, nausea, and vomiting were denied.

The patient has had a history of hypertension and diabetes mellitus since approximately three years ago. There was no history of trauma, as well as allergies. There is a history of cataract surgery in both eyes. Before hospital admission, the routine medications the patient took included candesartan 1x8mg, atorvastatin 1x20mg, and metformin 1x500mg.

The patient went to the ophthalmologist, and said that the eye condition at that time was caused by diabetes and was given methylcobalamin 3x500 mg and was referred to a neurologist. The neurologist did a Cranial CT Scan (no reading) and was given analgesics (metamizole sodium + diazepam) 3x500mg and Pregabalin 2x1 cap. Then after the patient moved to another hospital, the patient was treated as an inpatient for eight days. At the time, the

patient was diagnosed primarily with cellulitis of the left eye orbit.

On physical examination, he had a blood pressure of 110/70 mmHg, a regular heart rate of 80 beats per minute, SpO<sub>2</sub> of 98% room air, a temperature of 37.0°C and a respiratory rate of 20 times per minute. The patient had cavities in the upper right and lower left molars.

On his neurologic and ophthalmologic examination, the patient was compos mentis (GCS 15 E4M6V5) with no meningeal signs. Anisocoria 2mm/4mm, direct light reflex +/-, indirect light reflex -/-. His left eye was proptosis, redness and oedema on the palpebral, ptosis, conjunctival redness, complete ophthalmoplegia (oculomotor, trochlear, and abducens nerve), and vision loss (no light reflex; optic nerve). There were left ophthalmic nerve (V1) and peripheral facial nerve palsy. Motoric strength was (5555 / 5555)/(5555 / 5555), physiological reflexes were normal and pathological reflexes were absent.

Sinus/orbital and cerebral CT with contrast was performed while the patient was admitted to the Z hospital. A cerebral CT scan with contrast revealed a subperiosteal retroorbital abscess medial Sinistra extending to the orbital apex with suspected optic nerve compression, periorbital cellulitis, bilateral maxillary and sphenoid sinusitis.

### RESEARCH RESULT

Non-contrast cerebral CT scan at admission (11 days after contrast cerebral CT scan) was shown proptosis bulbus oculi Sinistra, infraorbital fat stranding and edema soft tissue regio maxilla, periorbita superior left the orbital

region to suggest inflammation, pansinusitis, a sign of small vessel ischemic lesion on bilateral corona radiata dd/ lacunar infarction, there were no bleeding or space-occupying lesion, small hyperdense

in the medial left temporal region suspect calcification, and focal cerebral atrophy (Figure 1 and 2). Chest X-ray showed increased bronchovascular markings (Figure 3).

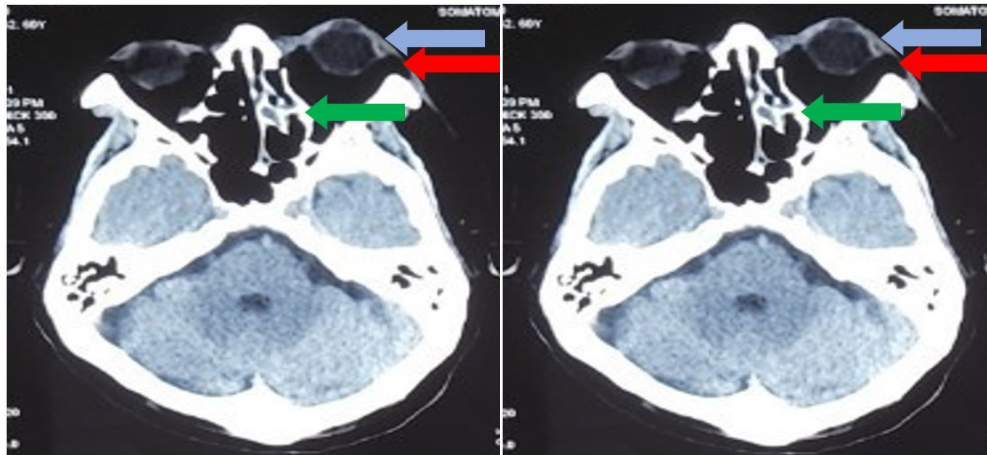


Figure 1. (A) Proptosis Of The Left Eye (Red Arrow), Intraorbital Fat Stranding (Blue Arrow), Mucosal Thickening On Ethmoid Sinus (Green Arrow); (B) Soft Tissue Edema On The Left Maxilla (Red Arrow)

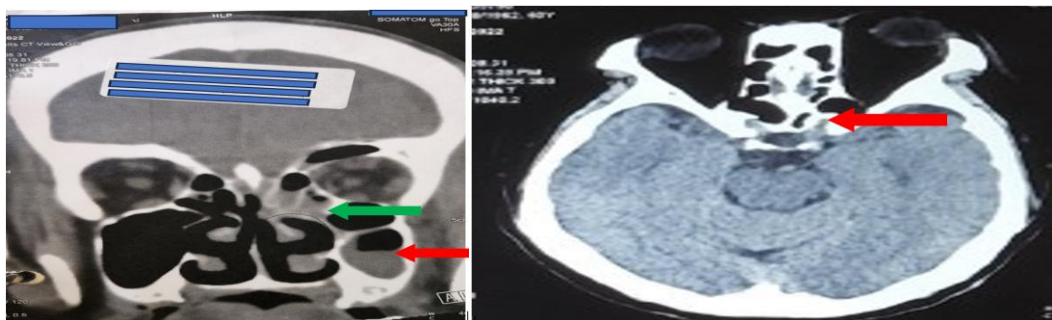


Figure 2. Sinusitis, (A) Mucosal Thickening On Left Maxillary Sinus (Red Arrow) And Osteomeatal Complex (Green Arrow); (B) Mucosal Thickening On Sphenoid Sinus (Red Arrow)

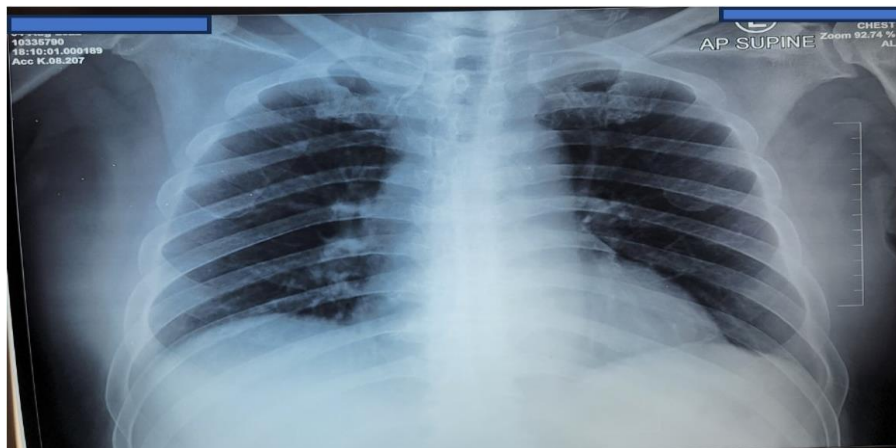

Figure 3. Chest X-ray AP Supine

Abnormal results from laboratory investigations at admission were included (Table 1). Other laboratory investigations were normal

Table 1. Laboratory Investigations

Parameter	Result	Normal value
Glucose	218	70-180mg/dL
Albumin	2.2	3.4-5.0 g/dL
Natrium	131	137-145 mmol/l
ESR	>140	2-30 mm/hour
D-Dimer	1,892	<500 ng/mL
Hs-CRP	234.64	0-3.3 mg/L
Anti-HIV	Reactive	Nonreactive

The clinical diagnosis is orbital apex syndrome ocular sinistra with facial nerve palsy, pansinusitis, left orbital cellulitis, hypo albumin, hyponatremia, diabetes mellitus, hypertension, and HIV.

Table 2. Differential Diagnosis Of Orbital Apex Syndrome

Features	OAS	SOFS	CSS
Optic nerve lesion	+, early	-	+, late
Ophthalmoplegia (CN III, IV, VI)	+	+	+, might be bilateral
Facial sensory loss distribution	CN V <sub>1</sub> ± V <sub>2</sub>	CN V <sub>1</sub>	CN V <sub>1</sub> ± V <sub>2</sub>
Internal carotid artery involvement	-	-	Present

Regarding patient management, the patient received joint care from a neurologist, ophthalmologist, and

otorhinolaryngologist. The planned investigation includes obtaining a blood and CD4+ count. Intravenous fluid NaCl 0,9% 500cc/12 hour. Broad-spectrum antibiotic with vancomycin 2x1g and meropenem 4x1g. Fluconazole caps 1x200mg for fungal coverage, NaCl caps 3x500mg for correction of hyponatremia. Albumin 25% for two days to correct hypoalbumin. Dietary management is applied for diabetes with rapid-acting insulin if indicated.

Four days after being hospitalized and initial treatment, the patient was scheduled for incision and drainage with functional endoscopic sinus surgery technique by the otorhinolaryngologist. Patient under general anesthesia. There were necrotic on the left middle turbinate. Concomitantly, uncinectomy and anterior ethmoidectomy were done. A sample from the sinus was collected for culture. After surgery, tampons were inserted.

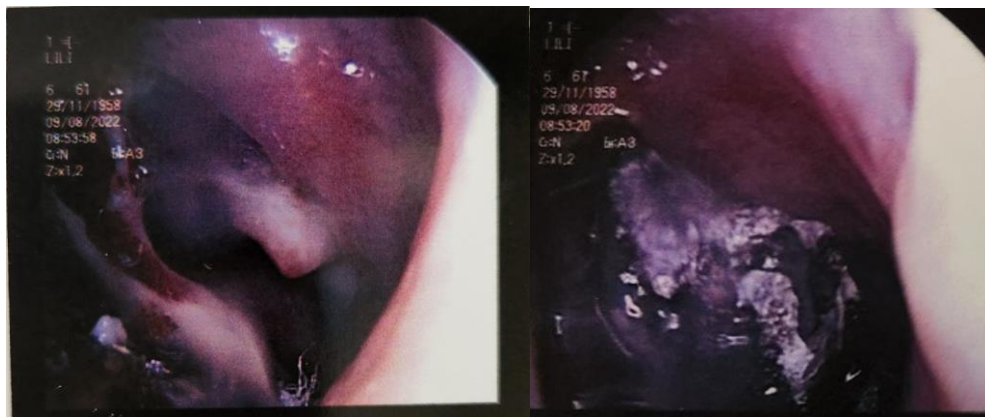


Figure 4. Functional endoscopic sinus surgery

## DISCUSSION

Orbital Apex Syndrome, also referred to as Jacod syndrome, is a collection of clinical manifestations caused by various potential conditions that exert pressure or impact the structures passing through the orbital apex (El-Feky, 2022). It is usually unilateral, although in some cases, it can be bilateral (Hung et al., 2019).

The orbital apex is the posterior region of the eye socket where the four walls of the orbit come together. It includes the optic canal and the superior orbital fissure. The optic canal houses the optic nerve, surrounded by protective membranes, as well as the ophthalmic artery that extends into the cranial cavity. Adjacent to

the optic canal, the superior orbital fissure is divided into superior, middle, and inferior portions by a ring of thickened periorbital called the annulus of Zinn, which covers the orbital bones (Pittner & Patel, 2022).

The common tendinous ring, located within the middle part of the superior orbital fissure, serves as a pathway for several important structures. In the superior portion of the fissure, it allows the passage of the lacrimal nerve (CNV1), frontal nerve (CNV1), trochlear nerve (CNIV), the superior branch of the ophthalmic vein, and recurrent meningeal artery. The middle part of the fissure permits the transmission of the nasociliary

nerve (CNV1), abducens nerve (CNVI), as well as the superior and inferior branches of the oculomotor nerve (CNIII). Lastly, the inferior portion of the fissure accommodates the inferior branch of the ophthalmic vein. (Badakere & Patil-Chhablani, 2019; Pittner & Patel, 2022).

The causes of this condition encompass a range of factors including vascular issues (such as carotid-cavernous fistula and aneurysm), inflammatory conditions (such as giant cell arteritis, Wegener's disease, systemic lupus erythematosus, sarcoidosis, Tolosa-Hunt syndrome, Churg-Strauss syndrome), neoplastic conditions (such as lymphoma, head and neck cancers, neural tumors), iatrogenic factors (such as complications from orbital and sino-nasal surgeries), traumatic incidents (such as cranio-maxillofacial injuries), and infectious sources (Badakere & Patil-Chhablani, 2019; Bennett et al., 2015).

Infection usually causes OAS in the adjacent posterior ethmoid or sphenoid sinuses, and most cases are due to invasive mold infections (e.g. *Mucormycosis*). Rhinocerebral mucormycosis is an opportunistic pathogen commonly found in immunocompromised individuals (Bhandari et al., 2022). Rare cases of OAS are due to bacteria (e.g., *S.aureus*, syphilis) and virus (e.g., Herpes zoster) (Bennett et al., 2015; Chiew et al., 2022). Sinusitis causes up to 90% of all preseptal and orbital infections (Bennett et al., 2015). In this case, the patient has pansinusitis.

It is possible that the patient's cavities in the upper right and lower left molars could be causing a long-standing teeth infection that spreads to the maxillary sinus and other sinuses and then orbital structures.

However, this occurrence is rare and only accounts for 2-5% of all cases of orbital cellulitis. The absence of dental symptoms might indicate another potential source of the infection (Xiang et al., 2022).

A mere fraction, constituting less than 1% of all cases of orbital cellulitis, ultimately progresses to developing Orbital Apex Syndrome (OAS). More than half of these instances are observed in individuals diagnosed with diabetes mellitus. Within the diabetic population, the predominant causative agent responsible for OAS is overwhelmingly identified as rhinocerebral mucormycosis (Duker & Yanoff, 2020). The presence of acidosis disrupts the ability of transferrin to bind to iron, leading to an increase in unbound iron levels and facilitating the growth of fungi (Jiang et al., 2016). Moreover, diabetic patients often experience polymorphonuclear dysfunction, characterized by delayed margination, thus promoting the proliferation of fungi. Bronchoalveolar macrophages in diabetic individuals exhibit a reduced capacity to inhibit spore germination (Godinho et al., 2021).

Patients with OAS commonly experience a combination of complete ophthalmoplegia, ptosis (drooping of the eyelid), reduced corneal sensation, and vision loss. Optic nerve-related symptoms, such as a relative afferent pupillary defect, tend to develop. In the early stages, minor swelling of the surrounding eye structures and orbital congestion may be present, which worsen as the disease advances. Proptosis (bulging of the eye) is frequently observed, although patients may not always report pain (Aryasit et al., 2013). Initially, eschars are infrequently observed, but if the condition remains untreated, they typically

form around the orbit (Bagheri et al., 2021). In this case, the clinical features of all the cranial nerves involved were present.

However, facial nerve involvement in association with OAS is an unusual presentation. Our patient has left facial nerve palsy. It is essential to note the close relationship between the orbital apex, petrous apex and pterygopalatine fossa. The occurrence of facial nerve paralysis together with rhino-orbital-cerebral mucormycosis was reported to be 11 percent according to a study by Hosseini and Borghei in 2005 (Hosseini & Borghei, 2005). While the exact mechanism behind facial nerve paralysis is not understood, it is commonly observed in diabetic patients due to pathological changes in the arteries, leading to ischemia and compression.

It is essential to perform neuro-imaging in individuals presenting with orbital apex syndrome. Brain and orbit MRI with or without contrast and CT with contrast, including the paranasal sinuses, is the imaging modality of choice.

Sinus samples commonly display the presence of infectious organisms. To determine the existence of Gram-positive or Gram-negative bacteria, it is necessary to conduct bacterial Gram staining. Furthermore, staining methods involving India ink and specific stains for fungi should be utilized to assess the presence of mucormycosis. *Mucor* and *Rhizopus* species can be identified by observing nonseptate, large, branching hyphae that readily stain with Hematoxylin and Eosin (HE). (Duker & Yanoff, 2020).

The treatment focuses on addressing the root cause of the condition. It is crucial to differentiate between inflammatory

Interestingly, this condition typically spares the taste sensation, which is controlled by the chorda tympani nerve, as observed in this patient (Ferguson, 2000).

The patient was recently diagnosed with HIV. A patient's immunodeficient condition may play a role in the pathogenesis of OAS and act as a predisposing factor (Bhandari et al., 2022).

The superior orbital fissure syndrome (SOFS), OAS, and cavernous sinus syndrome (CSS) are contiguous, with similar etiologies. Clinical distinctions between these syndromes were described (Table 2) (Bennett et al., 2015; Duker & Yanoff, 2020; Pittner & Patel, 2022).

### **Differential Diagnosis of Orbital Apex Syndrome**

causes and infections, particularly fungal infections, as they can rapidly worsen and become life-threatening if treated with steroids. In certain cases, surgical procedures like sinus exenteration or orbital exenteration may be necessary to enhance chances of survival.

Management may require neurosurgery for aneurysms, tumours, and trauma. Systemic antibiotics (vancomycin 1 g IV q12h and ceftazidime 1 g IV q8h for *Staphylococcus* and *Streptococcus*) penicillin G (2.4 million U IV q4h for 10-14 days; then 2.4 million U IM q week for three weeks) for syphilis. Systemic antifungal (amphotericin B 0.25-1.0 mg/kg IV over 6 hours) for mucormycosis (Friedman et al., 2019).

The prognosis of patients with OAS is determined by the etiology, the extent of nerve injury, and the treatment modality. The mortality rate associated with infectious orbital apex syndrome, particularly mucormycosis-induced

cases, ranges from 46% to 52% despite treatment with amphotericin B. Significant morbidity is observed as many patients require surgical removal of the sinuses and orbit (exenteration). Permanent neurological impairments are frequently observed. Involvement of the internal carotid artery and the development of cavernous sinus thrombosis are common, but typically occur in cases that have been present for an extended duration (Martel et al., 2015).

It is important to note as information bias might affect the quality and interpretation.

#### CONCLUSION

Orbital apex syndromes can have various causes including inflammatory conditions, trauma, tumors, and infections. It is crucial to conduct a thorough clinical examination, along with appropriate paraclinical investigations and imaging, to accurately diagnose the condition and initiate appropriate treatment. Determining underlying cause is especially important because specific treatments like corticosteroids may be beneficial for certain disorders, such as inflammatory causes. However, they can be harmful for others, such as infections.

#### REFERENCE

- Aryasit, O., Preechawai, P., & Aui-Aree, N. (2013). Clinical Presentation, Aetiology and Prognosis of Orbital Apex Syndrome. *Orbit*, 32(2), 91-94. <https://doi.org/10.3109/01676830.2013.764439>
- Badakere, A., & Patil-Chhablani, P. (2019). Orbital Apex Syndrome: A Review. *Eye and Brain*, 11, 63-72. <https://doi.org/10.2147/EB.S180190>
- Bagheri, M., Jafari, A., & Jafari, S. (2021). Orbital apex syndrome in COVID-19 patient, a case report. *Visual Journal of Emergency Medicine*, 23, 101006. <https://doi.org/10.1016/j.visj.2021.101006>
- Bennett, J. E., Dolin, R., & Blaser, M. J. (Eds.). (2015). *Mandell, Douglas, and Bennett's Principles and Practice of Infectious Diseases* (8th ed.). Elsevier. <https://doi.org/10.1016/C2012-1-00075-6>
- Bhandari, J., Thada, P., & Nagalli, S. (2022). *Rhinocerebral Mucormycosis*. StatPearls. <https://www.ncbi.nlm.nih.gov/books/NBK559288/>
- Chiew, Y. R., Ng, G. J., Kong, Y., & Tan, Y. J. (2022). Orbital apex syndrome secondary to herpes zoster ophthalmicus: Clinical features and outcomes case report and systematic review. *Journal of Clinical Neuroscience*, 99, 367-372. <https://doi.org/10.1016/j.jocn.2022.03.036>
- Duker, J. s, & Yanoff, M. (Eds.). (2020). Urgent Neuro-Ophthalmic Disorders. In *Ophthalmology* (5th ed., p. 986). Elsevier.
- El-Feky, M. (2022, March 29). *Orbital apex syndrome*. Radiopaedia.Org; Radiopaedia.org. <https://doi.org/10.53347/RID-98544>
- Ferguson, B. J. (2000). Mucormycosis of the nose and paranasal sinuses. *Otolaryngologic Clinics of North America*, 33(2), 349-365. <https://doi.org/10.1016/S0030>



- 6665(00)80010-9  
Friedman, N. J., Kaiser, P. K., Pineda, R., & Massachusetts Eye and Ear Infirmary. (2019). Ocular Motility and Cranial Nerves. In *The Massachusetts eye and ear infirmary illustrated manual of ophthalmology*.
- Godinho, G., Abreu, I., Alves, G., Vaz, R., Leal, V., Carvalho, A. C., Sarmiento, A., & Falcão-Reis, F. (2021). Orbital Apex Syndrome due to Orbital Mucormycosis after Teeth Infection: A Successful Case Report. *Case Reports in Ophthalmology*, 12(1), 110-115.  
<https://doi.org/10.1159/000510389>
- Hosseini, S. M. S., & Borghei, P. (2005). Rhinocerebral mucormycosis: pathways of spread. *European Archives of Oto-Rhino-Laryngology: Official Journal of the European Federation of Oto-Rhino-Laryngological Societies (EUFOS): Affiliated with the German Society for Oto-Rhino-Laryngology - Head and Neck Surgery*, 262(11), 932-938.  
<https://doi.org/10.1007/S00405-005-0919-0>
- Hung, Y. C., Chiu, M., & Elder, M. J. (2019). Bilateral orbital apex syndrome secondary to sinusitis. *Clinical & Experimental Ophthalmology*, 47(6), 806-807.  
<https://doi.org/10.1111/CEO.13497>
- Jiang, N., Zhao, G., Yang, S., Lin, J., Hu, L., Che, C., Wang, Q., & Xu, Q. (2016). A retrospective analysis of eleven cases of invasive rhino-orbito-cerebral mucormycosis presented with orbital apex syndrome initially. *BMC Ophthalmology*, 16(1), 10.  
<https://doi.org/10.1186/s12886-016-0189-1>
- Martel, J., Anders, U., Taylor, E., & Martel, J. (2015). Acute orbital apex syndrome and rhino-orbito-cerebral mucormycosis. *International Medical Case Reports Journal*, 93.  
<https://doi.org/10.2147/IMCRJ.S83036>
- Pittner, A., & Patel, P. (2022). *Orbital Apex Syndrome - EyeWiki*. American Academy of Ophthalmology.  
[https://eyewiki.aao.org/Orbital\\_Apex\\_Syndrome](https://eyewiki.aao.org/Orbital_Apex_Syndrome)
- Xiang, W., Wei, H., Xu, L., & Liang, Z. (2022). Orbital apex syndrome secondary to apical periodontitis of a tooth: a case report. *BMC Neurology*, 22(1), 354.  
<https://doi.org/10.1186/s12883-022-02890-0>