

SEGMENTAL RESECTION OF MANDIBLE FOR TREATMENT UNICYSTIC AMELOBLASTOMA: A CASE REPORT**Fadli Ashar^{1*}, Eka Marwansyah², Andri Hardianto³**¹⁻³Universitas Padjadjaran, West Java - Indonesia²Hasan Sadikin General Hospital, West Java - Indonesia

Corresponding author: fadli20002@mail.unpad.ac.id

Disubmit: 04 Juli 2022

Diterima: 24 Juli 2022

Diterbitkan: 01 Oktober 2022

DOI:

ABSTRACT

Ameloblastoma is the most common odontogenic tumour as it usually does not form metastasis, it is considered as benign tumour with a locally invasive growth pattern and destruction of the jaw and the surrounding tissue. Ameloblastoma annual incidence is 0.5 per 1.000.000 people, higher incidences are found in Africa, China and India in comparison with the western countries. About 80% of ameloblastomas are located in mandible, mainly in the third molar region, and 20% in the maxilla, particularly in the posterior region. Unicystic ameloblastoma is associated with a smaller relapse risk and is the only type that is susceptible for conservative surgery. Standar treatment for ameloblastoma today is radical resection with 1 cm resection margins. Recurrence range from 0 to 15% conservative surgery including enucleation and curettage recurrence rates as high as 55%. Recurrence ameloblastoma problem are associated with development of metastasis and transformation into ameloblastic carcinoma. Segmental resection with adequate margins followed by reconstruction with AO Plat the most ideal form of treatment available. Dentoalveolar rehabilitation is recommended in all such patients to improve final outcome.

Keywords: Ameloblastoma, Segmental Resection, Reconstruction**INTRODUCTION**

Ameloblastoma is an uncommon tumor originating from dental epithelium most involving the mandible. Its clinical behaviors lie somewhere between benign and malignant in that it is a slowly progressive disease but is locally invasive. Lesion is asymptomatic and as the disease progresses, symptom like a pain, loosening of teeth, facial asymmetry and difficulty in articulation may appear (Mendenhall WM, Werning JW, Fernandes R, Malyapa RS, Mendenhall NP, 2007).

Standard treatment for ameloblastoma is radical resection with 1 cm resection margins. Recurrence rates range from 0 to 15%. For more aggressive type of ameloblastoma, such as the granular cell type, even greater resection margins may be required (Masthan, K. M., Anitha, N., Krupaa, J., & Manikkam, S. 2015). Conservative surgery including enucleation and curettage yield recurrence rates as high as 55%⁴ and is only considered feasible for unicystic ameloblastoma with

luminal growth pattern. Treatment of mandibular ameloblastoma remain controversial, but there is now little doubt that radical resection has the advantage of lower recurrence over conservative procedures (Dandriyal, R., Gupta, A., Pant, S., Baweja, H. H. 2011). Recurrence rate was less than 25% for all types unicystic ameloblastoma and 10.7% for luminal/intraluminal types and there is a spectrum of biological behavior 2. If recurrence is considered as the key factor, odontogenic keratocyst also show higher recurrence rate compared to unicystic ameloblastoma (Blanas, N., Freund, B., Schwartz, M., Furst, I. M. 2000).

True unicystic ameloblastoma are considered to be a less aggressive form of ameloblastoma and can be successfully treated by simple enucleation or less aggressive surgery (lie et). Recurrence after conservative treatment of unicystic ameloblastoma is reported between 10 and 25% but these reports do not specify the histologic subtypes of the primary lesion. Due to this, many professionals choose resection as treatment, many case series have conclude that there were low recurrences following conservative treatment of true unicystic ameloblastoma (Siriwardena, B. S. M. S., Tennakoon, T. M. P. B., Hunter, K. D., & Tilakaratne, W. M. 2018).

This case report presented a case of 32-year-old male patient with unicystic ameloblastoma who was treated with segmental resection on his mandible.

LITERATURE REVIEW

Ameloblastoma is a benign odontogenic tumor that grows slowly and is locally invasive. This tumor shows signs of a histopathologically benign tumor, clinically aggressive and destructive (Wright, J. M., & Tekkesin, M. S. 2017). Ameloblastoma is more common in the mandible than the maxilla (Effiom, O. A., Ogundana, O. M., Akinshipo, A. O., & Akintoye, S. O. 2018). The recurrence rate of ameloblastoma is very high (Laborde, A., Nicot, R., Wojcik, T., Ferri, J., & Raoul, G. 2017). The aim is to provide information about segmental resection of mandible for treatment unicystic ameloblastoma.

METHODS

A 32-year-old male patient came with a chief complaint of swelling in the right lower jaw. Initially, the complaint was felt 5 years ago with swelling, but no pain during palpation and percussion on right lower jaw. The patient general health was good, and blood test results showed no history of systemic disease.

Extraoral examination (Figure 1) revealed asymmetry of the right face in the lower right area. The skin color was the same as the surrounding tissue, with hard consistency, no tenderness, and normal temperature. Intraoral examination (Figure 2) revealed poor oral hygiene, multiple dental caries and missing teeth. a single diffuse swelling measuring 3 cm × 2 cm in size extending from 31-47 region with obliteration of buccal vestibule.

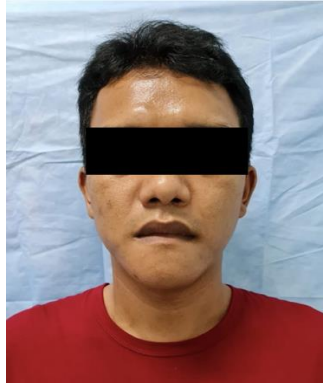

Figure 1. Patient profile condition

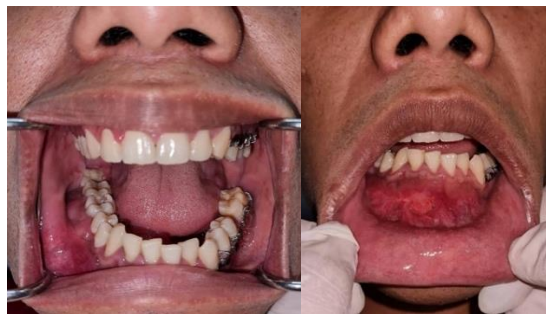

Figure 2. Intraoral examination.

Panoramic radiograph (Figures 3) was performed and it showed a defect along the right mandibular, a bubble soap with mixed radiolucent and radio-opaque

appearance with ill-defined periphery extending from 34 to 47 region to the inferior border of the mandible.

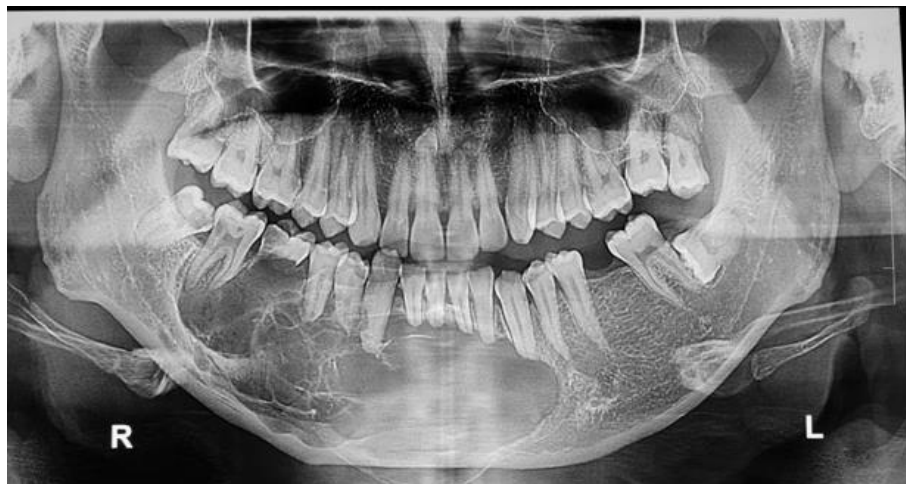

Figure 3. Panoramic radiograph.

Based on clinical and radiological examination, the patient was diagnosed with unicystic ameloblastoma. A segmental resection of mandible was performed under general

anesthesia and multiple sections were made from different locations of the gross specimen. The mandible was cauterized, and the bone was cut using a saw and it was smoothed. The gross specimen was

glistening, reddish brown in colour indicating extensive vascularity, firm in consistency and measuring 10 cm × 6 cm. Extraction of teeth 48 and 34 was also done along with the segmental resection. An AO L

plate was placed on the right mandible after the specimen out. The surgical wound was closed neatly, starting from muscle suturing up to the intra and extraoral.

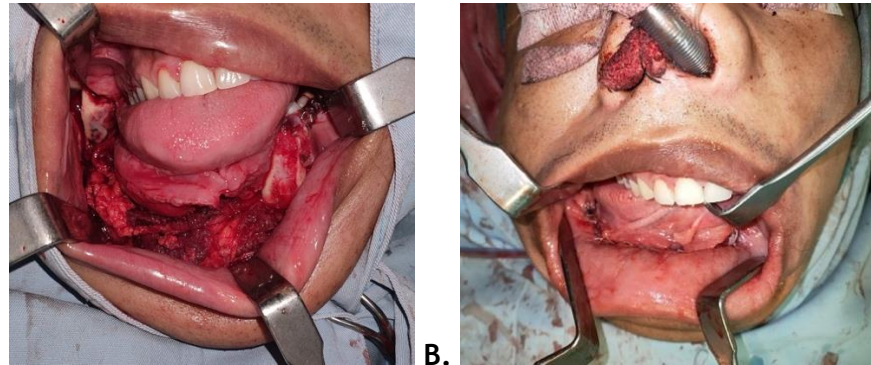


Figure 4. A. segmental resection was performed under general anesthesia B. closed surgical wound

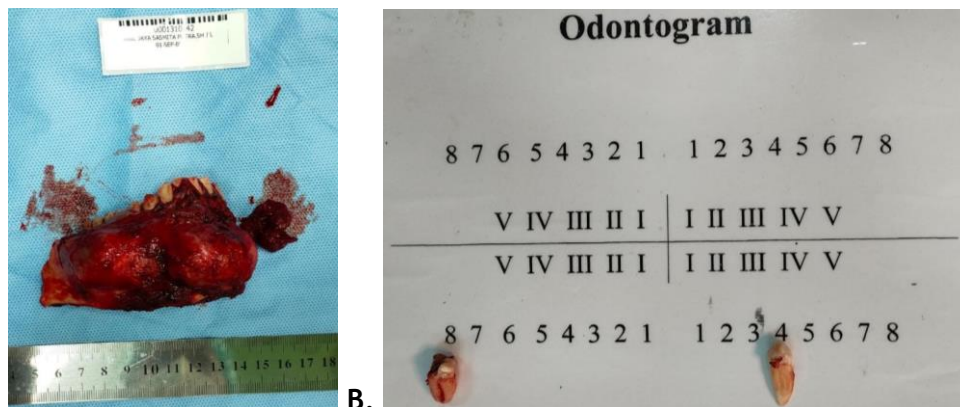


Figure 5. A. resected mandible B. extracted teeth 48 and 34

Affecting was performed on the first and third week after surgery, there was no signs of

infection, the affecting was performed alternately, and centric occlusion was checked.

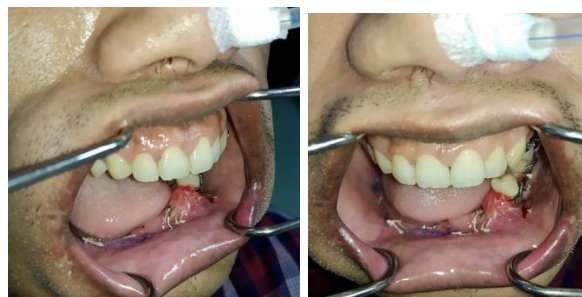

Figure 6. Post-operative day VII

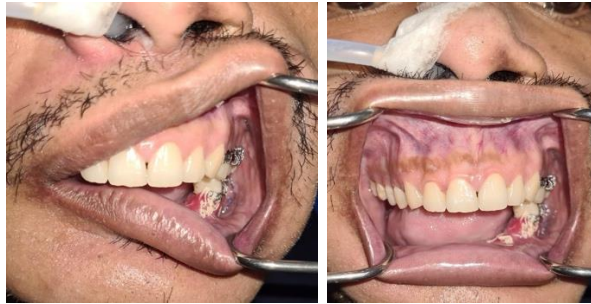

Figure 7. Post-operative day XXI

DISCUSSION

Ameloblastoma is a neoplasm of odontogenic epithelium, principally of enamel organ-type tissue that has not undergone differentiation to the point of hard tissue formation. It accounts for about 1% of all oral tumors and about 9-11% of odontogenic tumors. It is generally a slow-growing but locally invasive tumor (Masthan KM, Anitha N, Krupaa J, Manikkam S. 2015). This tumor was classified by WHO into solid/multicystic, extraosseous/peripheral, demoplastic, and unicystic ameloblastomas.

This case report presented a patient who diagnosed with unicystic ameloblastoma. The term unicystic is derived from the macroscopic and microscopic appearance of the lesion. It is a well-defined, often large monocytic cavity with a lining focally, but rarely entirely composed of odontogenic (ameloblastomatous) epithelium. Predominant radiographical patterns for Unicystic Ameloblastoma are unilocular, scalloped, macromultilocular, pericoronal, interradicular, or periapical expansile radiolucencies. The unicystic type of ameloblastoma is one of the least encountered variant of the ameloblastoma was counted about 10-15% of all the cases. In this case report, the

patient came with swelling on his right lower jaw as the chief complaint without any pain sensation. Many benign lesions cause mandibular swellings, whose origin can be, attributed to odontogenic or non-odontogenic causes. The most commonly encountered are ameloblastomas, radicular cysts, DCs, OKCs, central giant cell granulomas, fibro-osseous lesions and osteomas (Elza S, et al. 2016).

The etiology of ameloblastoma is still uncovered, but most of it are associated with tooth impaction and the most common is the third molar impaction. Ameloblastomas are of ectodermal origin and derived from oral epithelium. The cells are only present during tooth development that deposit tooth enamel, which forms the outer surface of the crown. Ameloblasts become functional only after odontoblasts form the primary layer of dentin (the layer beneath enamel). The cells eventually become part of the enamel epithelium and eventually undergo apoptosis (cell death) before or after tooth eruption (Elza S, et al. 2016). There exist deposits of these cells in the structures in and around the tooth, termed cell rests of Malassez and cell rests of Serres. Current thought is that ameloblastomas can arise from either the cells mentioned above or other cells of ectodermal origin,

such as those associated with the enamel organ. However, this patient showed no unerupted tooth but the right lower third molar was impacted, so it was still unclear about the main etiology of this patient.

The radiograph examination was performed with orthopantomogram and showed a bubble soap with mixed radiolucent and radio-opaque appearance with ill-defined periphery extending from 34 to 47 region to the inferior border of the mandible. Unicystic ameloblastoma (UA) represents an ameloblastoma variant, presenting as a cyst that show clinical and radiologic characteristics of an odontogenic cyst (Masthan KM, Anitha N, Krupaa J, Manikkam S. 2015). The description of ameloblastoma in the literature White, S. C. (2014) shows that there is a radiolucent, well defined, corticated appearance, its location is from the molars to the mandibular ramus, the shape can be multilocular or unilocular, the internal structure is radiolucent and has a honeycomb or soap-bubble appearance. The patient was also presented with root resorption along with the lesion.

Treatment of ameloblastomas must be adapted to macroscopic and histologic characteristics of each tumor (Arlabous, M et al. 2018). Recurrence of ameloblastoma is directly related to the surgical approach. Recurrence with conservative treatment (enucleation) is high: from 60% to 90%. Resection with 1 to 2 cm. margin has been shown to result in lower recurrence rates but can be associated with greater morbidity, poor cosmetic, and functional outcomes. There are many options, ranging from curettage to extensive bone resections, and the

reconstruction may be carried out using plates and pins (Palanisamy, J. C., Jenzer, A. C. 2021). When the ameloblastoma reaches a larger volume, compromising a great portion of cortical bone and anatomical structures, there is a need of more invasive procedures, such as segmental resection with the discontinuity of the bone piece, even removing the periosteum and overlaying soft tissue. In this case report, a segmental resection was chosen to be the main treatment and an AO L plate was also placed to reconstruct the mandible. This treatment was chosen after several consideration.

According to the age, the patient was an adult, the facial growth had already stopped and it considered safe to use an invasive treatment. Otherwise, if the patient was a young age person, extensive procedures should be avoided, whereas conservative procedures are recommended (Maia, E. C. 2017). Another factor to be taken into consideration when choosing the surgical protocol is the anatomical site of the lesion, which directly influences on the pre-and post- assessment of treatment. When choosing between a radical or a conservative surgery, it is necessary to consider the size and the site of the tumor, as well as the clinical aspect of progression, the proximity with anatomical structures, histological characteristics, and systemic conditions of the patients. In the case of maxillary ameloblastomas, the choice of radical procedures is almost certain, because the spongy characteristic of maxillary bone facilitates the spread of the lesion. But due to the large of the lesion, this patient underwent segmental resection surgery even it occurred on his lower jaw. Treatment completion will be by a surgeon

trained in head and neck surgery, typically an oral and maxillofacial surgeon, otolaryngologist, plastic surgeon, or oncologic surgeon. Often, case planning can include either immediate or delayed reconstruction. Treatment planning is critical, especially when involving teeth, as extractions of teeth in the lesion are often completed and permitted to heal before access through the neck, thus preventing communication with the oral cavity and associated bacteria (Palanisamy, J. C., Jenzer, A. C. 2021).

In literature, the recurrence after conservative treatment of unicystic ameloblastoma is reported to be between 10 and 25% but these reports do not specify the histologic subtypes of the primary lesion. Due to this, many professionals choose resection as treatment. Therefore, in addition to analyzing the clinical and radiological data of the lesion, histopathological examination is of great importance for an accurate

diagnosis and consequently to choose the most appropriate treatment. Unfortunately, malignant ameloblastoma is too rare to estimate its prognosis. Due to its slow-growing nature, the malignancy may not occur for up to 10 years after initial resection of benign ameloblastoma (Palanisamy, J. C., Jenzer, A. C. 2021; Gracia, NG et al. 2016).

CONCLUSION

Ameloblastoma is a tumor that the etiology is still unknown. A thorough examination and proper diagnosis need to be carried out so that the treatment plan can be made as good as possible. The choice of treatment for this lesion is based on various considerations and requires good collaboration between disciplines. Prognosis and recurrence in patients are unlikely to occur in benign cases, but in malignant cases cannot be predicted.

REFERENCE

- Almeida Rde, A., Andrade, E. S., Barbalho, J. C., Vajgel, A., & Vasconcelos, B. C. (2016). Recurrence rate following treatment for primary multicystic ameloblastoma: Systematic review and meta-analysis. *International Journal of Oral and Maxillofacial Surgery*, 45, 359-367.
- Arlabous, M et al. (2018). Treatment of Mandibular Ameloblastoma Involving the Mandibular Condyle: Resection and Concomitant Reconstruction With a Custom Hybrid Total Joint Prosthesis and Iliac Bone Graft. *Journal of Craniofacial Surgery*. 2018;29(3) : e307-e314.
- Blanas N, Freund B, Schwartz M, Furst IM. (2000). Systematic review of the treatment and prognosis of the odontogenic keratocyst. *Oral Surg Oral Med Oral Pathol Oral Radiol Endod* 2000; 90:553-558.
- Cohen A, Laviv A, Berman P, Nashef R, Abu-Tair J. (2009). Mandibular reconstruction using stereolithographic 3-dimensional printing modeling technology. *Oral Surg Oral Med Oral Pathol Oral Radiol Endod*. 2009 Nov;108(5):661-6.
- Mendenhall WM, Werning JW, Fernandes R, Malyapa RS, Mendenhall NP. (2007). Ameloblastoma. *Am J Clin Oncol* 30: 645-648.

- Dandriyal R, Gupta A, Pant S, Baweja HH. (2011). Surgical management of ameloblastoma: conservative or radical approach. *Natl J Maxillofac Surg* 2:22-27.
- Effiom, O. A., Ogundana, O. M., Akinshipo, A. O., & Akintoye, S. O. (2018). Ameloblastoma: current etiopathological concepts and management. *Oral diseases*, 24(3), 307-316.
- Elza S, et al. (2016). A Historical Review of Ameloblastoma. *International Journal of Science and Research (IJSR)*. 2016. Vol (5): 156-158.
- Gracia, NG et al. (2016). Unicystic Ameloblastoma with Mural Proliferation Managed by Conservative Treatment. *Case Report in Pathology*. 2016.
- Laborde, A., Nicot, R., Wojcik, T., Ferri, J., & Raoul, G. (2017). Ameloblastoma of the jaws: Management and recurrence rate. *European annals of otorhinolaryngology, head and neck diseases*, 134(1), 7-11.
- Li T, Wu Y, Yu S, Yu G. (2002). Clinicopathological features of unicystic ameloblastoma with special reference to its recurrence. *Zhonghua Kou Qiang Yi XueZaZhi* 2002;37:210-212.
- Maia, E. C. (2017). *Sandrini FAL. Management techniques of ameloblastoma: a literature review*. *Rev Gaúch Odontol*. 2017;65:62-69.
- Masthan, K. M., Anitha, N., Krupaa, J., & Manikkam, S. (2015). Ameloblastoma. *Journal of Pharmacy & Bioallied Sciences*, 7, S167-S170.
- Palanisamy, J. C., Jenzer, A. C. (2021). Ameloblastoma. In: *StatPearls [Internet]*. Treasure Island (FL): StatPearls Publishing; 2021 Jan-. Available from: <https://www.ncbi.nlm.nih.gov/books/NBK545165/>.
- Siriwardena, B. S. M. S., Tennakoon, T. M. P. B., Hunter, K. D., & Tilakaratne, W. M. (2018). Unicystic ameloblastoma: Analysis of 370 cases in a single center in Sri Lanka. *Journal of Oral Pathology & Medicine*, 47(7), 706-709.
- White, S. C. (2014). *Pharoah MJ. Oral Radiology Principles and Interpretation*. 7th ed. St. Louis Missouri: Elsevier Mosby; 2014.
- Wright, J. M., & Tekkesin, M. S. (2017). Odontogenic tumors: where are we in 2017?. *Journal of Istanbul University Faculty of Dentistry*, 51(3 Suppl 1), S10.